

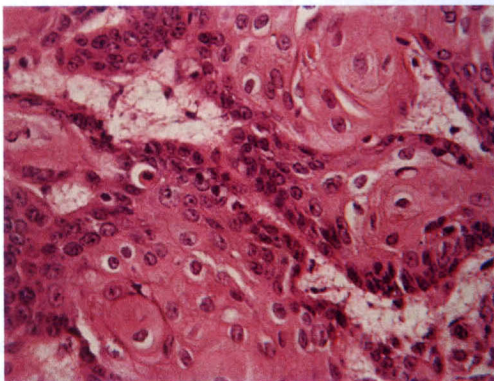
assess the endometrial status. So these were benign. Out of four cervical biopsies received all showed cervical cancer, carcinoma in situ (CIS). This indicates and emphasizes the need for early diagnosis of cervical cancer by cervical screening like Paps smear test. This must be ensured by the Gynaecologists.

Among the breast lesion 92.3% were benign and 7.7% were malignant. The age range of these patients were 15-52 years and the mean age were 31 years, as such most of the breast lesions came out as benign and one malignant case the age was 52 years. This is consistent with findings of others.

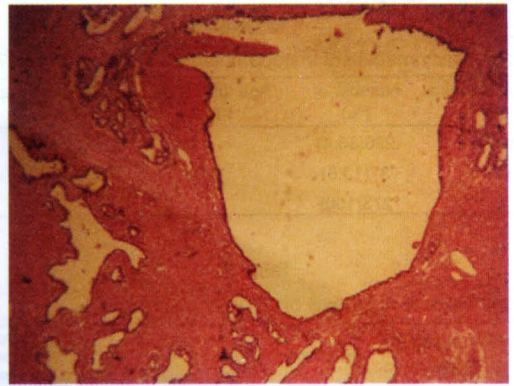
Among the total 19 appendix resected 26.31% were males, 73.65% were females, age range 14-78 years and the mean age is 38.94 years, Male female ratio M: F1:2.8. Out of this were acute and recurrent appendicitis was 55.6% and benign lesions were composed of obliteration of lumen by faecolith, lymphoid hyperplasia. was present in 33.3% cases and no case of malignancy was seen.

Conclusion

This study emphasizes the need and reaffirm the importance of Clinico-pathological correlation and sending of all surgically resected samples for histopathological diagnosis. Routine screening tests like Paps smear for all women above 35 years should be advised. Also any lesion in buccal mucosa, oropharynx, nasal mass, eye lesions should be sent for histological diagnosis. By doing these we will be able to diagnose malignant lesions early and can define better strategies for its early diagnosis and treatment plan. This will also reduce the increased morbidity and mortality in these patients.



Microphotograph1: Showing a squamous cell carcinoma, H&EX20 showing well differentiated anaplastic squamous cells and keratin pearl



Microphotograph2: Showing foci of adenomyosis, H&E 20 showing endometrial glands within myometrium

Acknowledgement

The authors gratefully acknowledge the permission of BIHS authority for allowing to review the records and the consultants for sending the samples for histopathology to BIHS

References

1. Robbins and Cotran Pathologic Basis of Disease. Editor Kumar, Abbas, Fausto. 7th edition, 2004 Publisher Elsevier India Ltd.
2. Talukdar SI, Haque MA, Huq MH et al. Histopathological analysis of hysterectomy specimens. *Mymensing Med J.* 2007;16(1):81-84
3. Talukdar SI, Haque MA, Alam MO et al. Histopathology based cancer pattern in Mymensing region of Bangladesh. *Mymensing Med J.* 2007;16(2):160-64
4. Talukdar SI, Haque MA, Alam MO et al. Gynecological cancers in surgical specimens in Mymensing, Bangladesh. *Bang J Pathol.* 2008; 23(1):2-5
5. Kyari O, Nggada H, Malrioga A. Malignant tumours of female genital tract in North Eastern Nigeria *J.* 2000; 77(10):334-8
6. Nkvekyer K. Pattern of gynecological cancers in Ghana. *East. Afr Med J* 2000; 77(10):334-8
7. Briggs ND, Katchy KC. Patterns of primary gynaecological malignancies as seen in the tertiary hospital situated in the rivers state of Nigeria. *Int J gynecol Obstet* 1990;31(2);157-61
8. You W, Dainty LA, Rose GS et al. Gynecologic malignancies in women aged less than 25 years. *Obstetric & Gynecology* 2005;105:1405-09
9. Chhabra S, Sonak M, Prem V et al. Gynecological malignancies in rural Institute in India. *J Obstet Gynecol* 2002; 22(4):426-29
10. Badar F, Anwar N, Meerza F et al. Cervical carcinoma in Muslim family. *Asian J Cancer Prev.* 2007;8(1):24-